

SHOULDER ARTHROSCOPY

SYNOVIAL AND
OSTEOCHONDRAL
PATHOLOGY



C.H.U. PARIS-OUEST



SHOULDER INVOLVEMENT

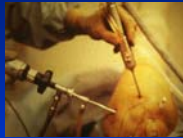- COMMON
- INFLAMMATORY ARTHRITIS
- SYNOVITIS
- NONOPERATIVE TREATMENT +++

C.H.U. PARIS-OUEST



SHOULDER INVOLVEMENT

- ARTHROSCOPY
 - DIAGNOSTIC
 - BIOPSY
 - TREATMENT
 - ALTERNATIVE TO OPEN TREATMENT
 - LAVAGE
 - SYNOVECTOMY
 - REMOVAL OF LOOSE BODIES



C.H.U. PARIS-OUEST



MOST COMMON SHOULDER INVOLVEMENT

- SERONEGATIVE SPONDYLOARTHROPATHIES
- SEROPOSITIVE RHEUMATOID ARTHRITIS
- PSEUDOGOUT GOUT
- REITER 'S SYNDROME
- JUVENILE RHEUMATOID ARTHRITIS

C.H.U. PARIS-OUEST



SERONEGATIVE SPONDYLOARTHROPATHIES

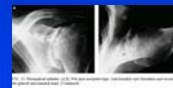- ANKYLOSING SPONDILITIS
- REACTIVE ARTHROPATHIES
- SACROILIAC JOINT
- LIMITED ROLE FOR ARTHROSCOPY
 - BIOPSY
 - ARTHROLYSIS ??

C.H.U. PARIS-OUEST



RHEUMATOID ARTHRITIS

- SHOULDER INVOLVEMENT
 - SERIOUS SYSTEMIC DISEASE
 - BILATERAL
 - 90% PATIENTS
- GLENOHUMERAL JOINT
- AC JOINT
- BURSA



C.H.U. PARIS-OUEST



RHEUMATOID ARTHRITIS

- COMPLETE CUFF TEAR 25 %
- INDICATIONS FOR ARTHROSCOPY
 - GLENOHUMERAL SYNOVECTOMY
 - AC JOINT RESECTION
 - BURSECTOMY
- EVOLUTED ARTHRITIS
- RARE UNTIL NOW

C.H.U. PARIS-OUEST



POLYMYALGIA RHEUMATICA

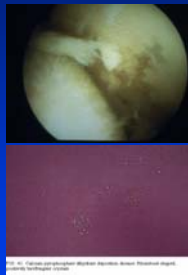
- COMMON
- MYALGIA + ARTHRALGIA
- SHOULDER AND PELVIC GIRDLE
- ORAL CORTICOSTEROID
- LIMITED INDICATION FOR SHOULDER ARTHROSCOPY

C.H.U. PARIS-OUEST



CHRYSTALLINE ARTHRITIS

- GOUT
- ELDERLY FEMALES
- ARTHROSCOPY
 - DIAGNOSTIC
 - BIOPSY
 - LAVAGE
 - DEBRIDEMENT
 - SYNOVECTOMY

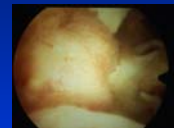


C.H.U. PARIS-OUEST



AMYLOIDOSIS

- EXTRACELLULAR DEPOSIT OF FIBROUS PROTEIN
- PRIMARY SECONDARY
- LONG TERM DIALYSIS
 - THICKENING OF THE CUFF
 - GLENOHUMERAL ARTHROPATHY
 - IMPINGEMENT
- BURSECTOMY AND ASD ???



C.H.U. PARIS-OUEST



PIGMENTED VILLONODULAR SYNOVITIS

- JOINT + BURSA
- HEMARTHROSIS
- SYNOVECTOMY
 - ARTHROSCOPY > OPEN
- SECONDARY SYNOVIORRHESIS

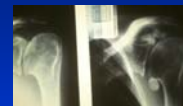

C.H.U. PARIS-OUEST



SYNOVIAL OSTEOCHONDROMATOSIS

- RARE
- BENIGN
- LOOSE BODIES
- MECHANICAL SYMPTOMS
- LOOSE BODIES REMOVAL
- SYNOVECTOMY

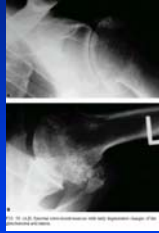

C.H.U. PARIS-OUEST



SYNOVIAL OSTEOCHONDROMATOSIS

- NUMBER SIZE
- BICIPITAL GROOVE
- BURSA
- AXILLARY POUCH
- MODIFIED APPROACH

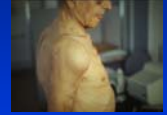

C.H.U. PARIS-OUEST



HEMOPHILIC ARTHROPATHY

- SPONTANEOUS INTRAARTICULAR HEMORRHAGE
- CHRONIC SYNOVIAL INFLAMMATION
- ARTHROSCOPIC LAVAGE
- LAVAGE
- INTRAOPERATIVE HEMOSTASIS

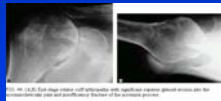
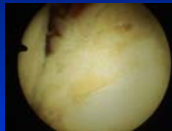
C.H.U. PARIS-OUEST



GLENOHUMERAL ARTHRITIS

- INTACT CUFF
 - LIMITED INDICATIONS
 - SURPRISE
- C.T.A.
 - TENOTOMY OF THE LHB
 - DEBRIDMENT
 - ASD

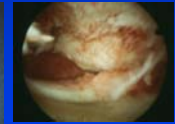
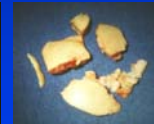

C.H.U. PARIS-OUEST



HUMERAL HEAD NECROSIS

- RARE INDICATIONS
- BIOPSY
- REMOVAL OF LOOSE BODIES



C.H.U. PARIS-OUEST



MECHANICAL SYNOVITIS

- FREQUENT
- ASSOCIATED
- CUFF TEAR
- CUFF TENDONITIS
- BICEPS TENDONITIS
- ANTEROSUPERIOR

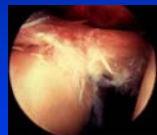
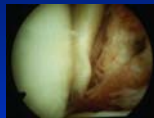

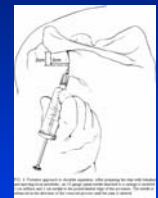Fig. 23. Anterior view of a right shoulder with acute DTS. Following the study of the joint, in the anterior quadrant, a large, irregularly shaped, loose body was removed. It contained a small amount of synovial tissue. This is considered to be a synovial body.

C.H.U. PARIS-OUEST



SEPTIC ARTHRITIS

- SAMPLE
- ADAPTED TO THE STAGE
 - LAVAGE
 - SYNOVECTOMY
 - OSTEOARTHRITIS = NO



C.H.U. PARIS-OUEST



CONCLUSION

- LIMITED INDICATIONS
- CONSERVATIVE TREATMENT
- BIOPSY
- LAVAGE
- SYNOVECTOMY
 - BETTER THAN OPEN
- MORE INDICATIONS IN THE FUTURE

